

# CASE REPORTS: SKIN TIGHTENING WITH A COMBINED UNIPOLAR AND BIPOLAR RADIOFREQUENCY DEVICE

Flor A. Mayoral MD

Flor A. Mayoral Dermatology Group, South Miami, FL

## Abstract

Monopolar radiofrequency (RF) devices are well established treatment modalities for tightening facial skin. A 60-year-old woman presented with a desire to tighten the lax skin and improve the appearance of both upper arms. A combination unipolar and bipolar RF device may provide volume reduction as well as skin tightening in the upper arm.

## Introduction

A variety of clinical studies have documented the ability of capacitively coupled monopolar radiofrequency (RF) energy (ThermaCool TC, Thermage, Inc., Hayward, CA) to noninvasively tighten facial skin by volumetric heating of the dermis. Other tissue-tightening RF devices are combinations in which bipolar RF energy is combined with diode laser energy<sup>1,2</sup> or with both diode laser and intense pulsed light energies.<sup>3</sup>

The Accent (Alma Lasers, Inc, Buffalo Grove, IL) RF system is designed for continuous skin contact using 2 handpieces: the unipolar to deliver RF energy to the subcutaneous adipose tissue for volumetric heating and the bipolar to deliver RF energy to the dermis for nonvolumetric heating. This case study compares the efficacies of the ThermaCool and the Accent in the treatment of skin laxity in the upper arm.

## Case Report

A 60-year-old woman (Fitzpatrick skin type III) presented with a desire to tighten the lax skin and improve the appearance of both upper arms. The patient had a history of breast cancer 4 years earlier and had been treated by lumpectomy.

The right arm was treated with the ThermaCool device. Exposure duration and cooling during each exposure period were controlled by a 3-cm<sup>2</sup> treatment tip. The patient's upper arm received 1200 pulses. Treatment settings were adjusted on the basis of patient feedback on discomfort (0-4; 4 = intolerable). Settings were changed when the discomfort level reached 2.5. Settings were 351.5 on the inner arm and 353.5 to 354.0 on the outer arm. The patient received a minimum of 6 passes on the inner arm and a minimum of three passes on the outer arm.

Due to the lengthy 2-hour duration of ThermaCool treatment, the author suggested that the left arm receive a single treatment with the Accent RF system. The patient was informed that the Accent RF system would require multiple treatments to achieve results. The patient consented to treatment with the ThermaCool on her right arm and a 30-minute treatment with the Accent on her left arm to see if the 2 devices would produce different results.

Using the unipolar (Accent) handpiece, the author treated the left arm to a maximum temperature of 42.5°C. The electrode tip was cooled during treatment to prevent thermal damage to the epidermis.<sup>4</sup> Three additional passes were done to maintain the treated area at the therapeutic temperature, as recommended by the manufacturer. The patient received no anesthesia, pretreatment care, or post-treatment care with either RF device.

Approximately 2 months later, the patient returned for evaluation of both upper arms. The skin of the ThermaCool-treated arm showed improvement in texture and smoothness as well as reduced wrinkling, especially on the inner part. The Accent-treated arm showed no differences. The patient was reminded that to compare the devices, she needed to have additional Accent treatments at 2-week intervals because the ThermaCool skin-tightening protocol calls for a single treatment with evaluation 4 to 6 months after treatment and the Accent protocol calls for multiple treatments.

Pre- and post-treatment photographs are shown in Figures 1 to 3. After the initial treatment session, the patient had 5 additional treatments at 2-week intervals with the Accent on the left arm (Figure 1) and no additional ThermaCool treatments on the right arm (Figure 2). On the seventh visit, the patient had had 6 Accent treatments on her left arm and a single ThermaCool treatment on her right arm 5 months earlier. The patient was pleased because her clothes no longer felt tight on her left arm. Although skin texture had improved in both upper arms, the skin of the Accent-treated arm was tighter and firmer (Figure 1). Photographs were taken of both arms during this visit and before the left arm received the seventh Accent treatment.

The patient continued to receive Accent treatments on the left arm at 2-week intervals while the right arm remained untreated. These Accent treatments were given with a combination of the unipolar and bipolar handpieces. After a total of 9 Accent treatments of her left arm, the patient asked the author to treat her right upper arm with the Accent device. The right ThermaCool-treated upper arm after 2 Accent treatments is shown in Figure 3. The patient was very satisfied with the improved tightness and firmness of her right upper arm. The patient commented that after

her ThermaCool-treated arm received 2 additional Accent treatments, her clothes fit better on that arm as well. No adverse effects were observed with either RF device.

### Discussion

For ThermaCool skin tightening, patients typically receive a single treatment that requires a treatment tip which cannot be reused. Additional treatments to improve results may be cost prohibitive to both the patient and clinician. Though multiple treatments are necessary for good results, the Accent does not require the purchase of a disposable tip, the treatments are shorter in duration, and improvement is noticeable after 2 or 3 treatments. A crucial step in gaining favorable results is slowly heating the skin to the patient's pain threshold, usually between 40°C and 44°C, and maintaining this temperature range for approximately 2 minutes, then moving to another area.

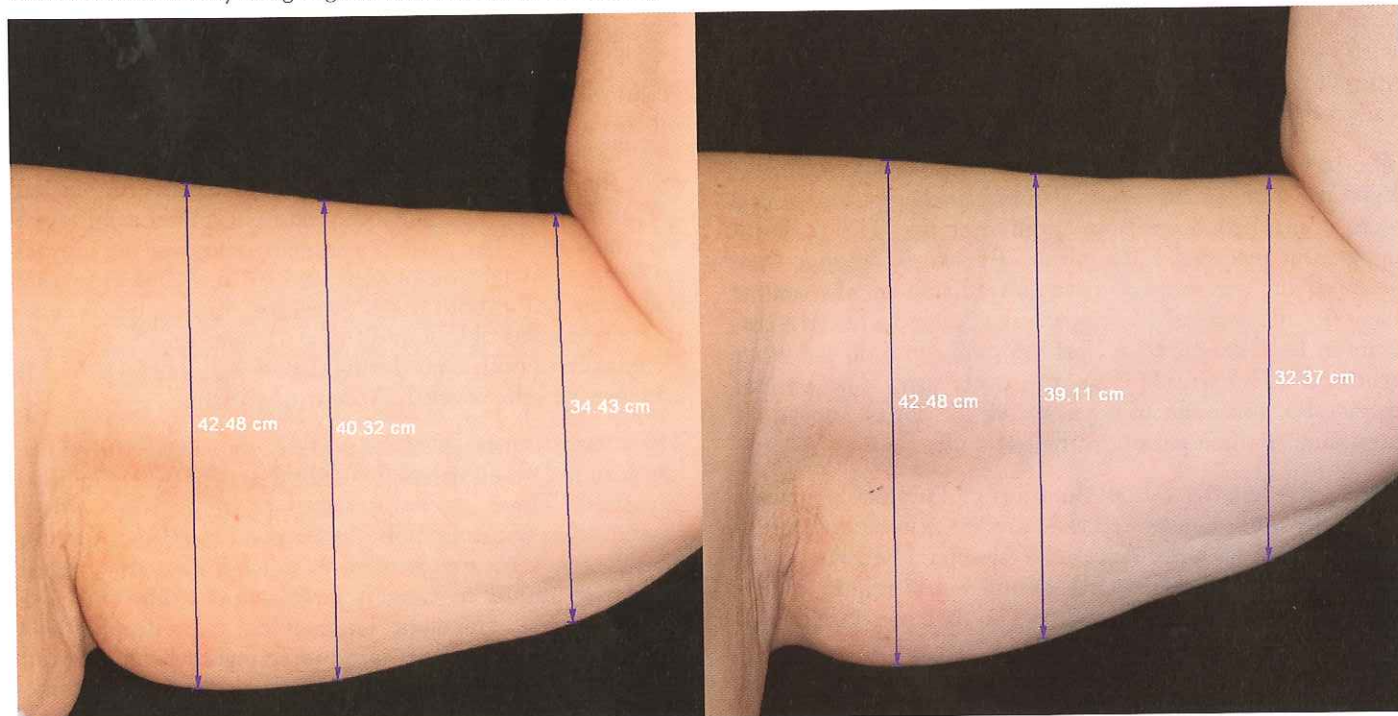
For this patient, the Accent may be the device of choice because (1) the patient's clothes fit better on the Accent-treated arm than on the ThermaCool-treated arm and (2) the patient's clothes fit better on the ThermaCool-treated arm only after several additional treatments with the Accent. The RF energy of the ThermaCool went only to the dermal layer of this woman's skin; therefore, the ThermaCool-induced changes were superficial in a patient whose primary cosmetic problem was excess volume rather than wrinkling. These observations suggest that when

patients require both tissue tightening and volume reduction in a nonfacial area, the Accent may be the treatment of choice because the RF energy penetrates deeper.

When the ThermaCool is used, tissue tightening occurs as a result of immediate collagen contraction and formation of new collagen months later.<sup>5</sup> An alternating current (6 MHz) causes charged particles in tissue to move, and this molecular motion produces heat.<sup>6</sup> Heat-induced denaturation of collagen typically occurs at 65°C. Multiple passes at moderate settings rather than single passes at higher settings have been suggested to avoid irregular contours and to reduce pain and adverse effects.<sup>7,8</sup> The epidermis is protected by contact cooling before, during, and after treatment.<sup>9</sup> The use of minimal anesthesia or pain blocking is also recommended so that patient feedback can be used as a guide to treatment settings.<sup>8,10</sup>

The results of this case study raise the question of the volume (fat) reduction by these devices. Most tissue-tightening studies of the ThermaCool have been done on the face, neck, or both. The depth of heating depends on the geometry of the treatment tip,<sup>11</sup> available in 1-, 1.5-, and 3-cm<sup>2</sup> sizes.<sup>12</sup> To the author's knowledge, although RF energy delivered by the ThermaCool device may reach the subcutaneous layer, volume (fat) reduction has not been studied extensively. One study suggested that stacked pulses applied to the submental region reduced fat content in that area.<sup>13</sup>

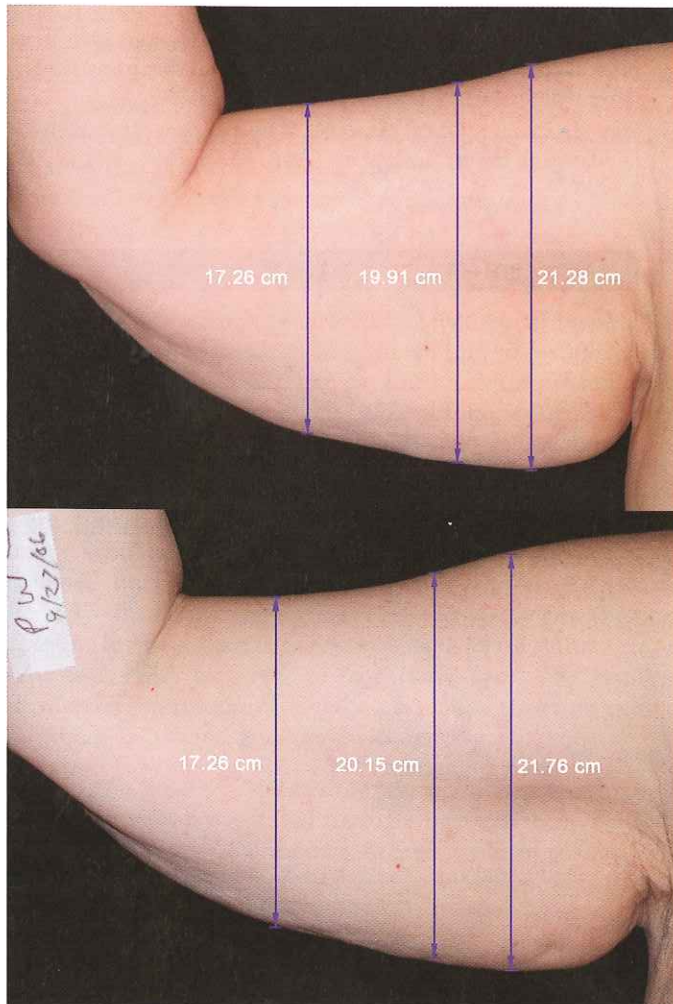
**Figure 1.** Dorsal view of the left upper arm of a 60-year-old woman before treatment (left) and 5 months after 6 treatments with the Accent radiofrequency device (right). The skin was noticeably smoother after treatment. The central measurement (right) shows a decrease of 1.21 cm (40.32-39.11 cm) and the near-elbow measurement shows a decrease of 2.06 cm (34.43-32.37 cm), indicating volume reduction in this Accent-treated arm. These findings are corroborated by the patient's comment that her clothes fit better on her left arm after the Accent treatments. Photographs were compared by using Mirror DPS version 7.0 (Canfield Clinical Systems, Fairfield, NJ). They were made the same size by using angiomas as landmarks and making them the same distance apart on the before and after images.



Hardaway and colleagues<sup>14</sup> suggested that “depending on cooling times, RF power, and electrode type, selective dermal heating can be achieved at levels as superficial as the papillary dermis and as deep as subcutaneous fat.” Ruiz-Esparza and colleagues<sup>15</sup> stated that a prototype of the ThermoCool “delivers heat to the dermis and beyond.” In an analysis of complication rates of the ThermoCool, Narins and colleagues<sup>10</sup> reported that overheating of deeper tissue may damage fat cells and over tighten fibrous septae, resulting in fat loss, deep fibrous scarring, and irregular skin-surface contours that may be corrected by subcision of fibrous tissue with microinjections of autologous fat.

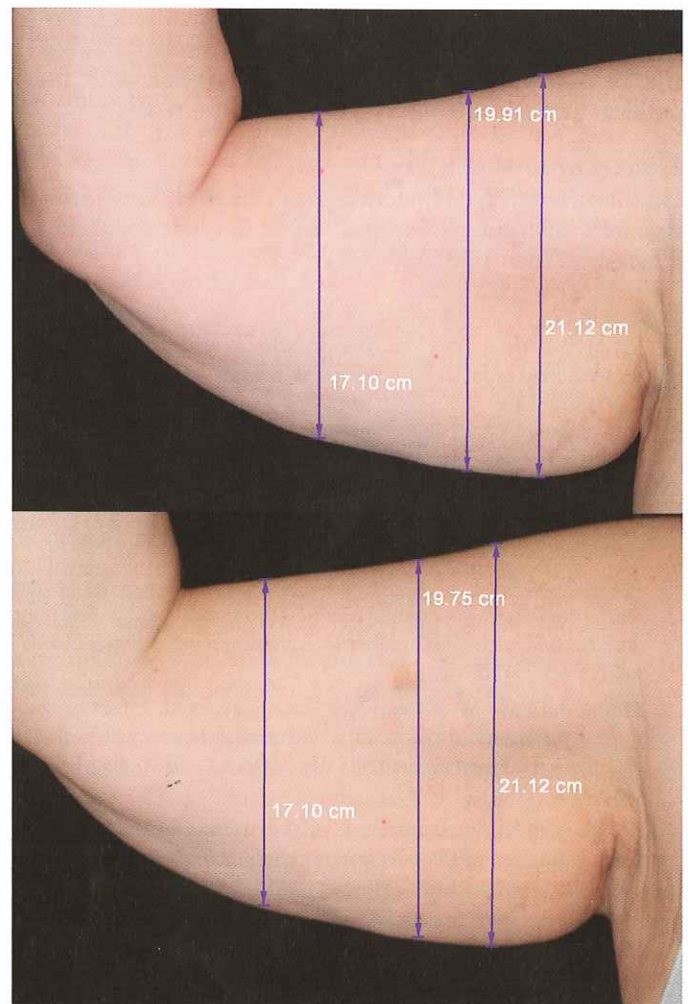
In the Accent system, RF energy is delivered through 2 handpiece applicators, one for unipolar energy and the other for bipolar energy. An alternating current of 40 MHz is gen-

**Figure 2.** Dorsal view of the right upper arm of a 60-year-old woman before treatment (top) and 5 months after a single treatment with the ThermoCool radiofrequency device (bottom). The measurements show skin tightening but no overall change in volume. Photographs were compared by using Mirror DPS version 7.0 (Canfield Clinical Systems, Fairfield, NJ). They were made the same size by using angiomas as landmarks and making them the same distance apart on the before and after images.



erated, considerably higher than the 6-MHz current of the ThermoCool, resulting in more heat generated due to the motion of charged particles. The energy from the unipolar handpiece penetrates 20 mm to the subcutaneous adipose tissue whereas the bipolar handpiece is designed to penetrate 2 to 6 mm to stimulate structural changes in the dermis.<sup>4</sup> Emilia del Pino and colleagues<sup>4</sup> showed that 68% of 26 patients treated twice with Accent RF energy on the buttocks and thighs achieved a 20% volumetric contraction effect, indicating that RF energy affects the connective tissue of the subcutaneous adipose tissue. The authors suggest that this effect would probably occur in other body areas as well.

**Figure 3.** Dorsal view of the right upper arm of a 60-year-old woman 5 months after a single treatment with the ThermoCool radiofrequency device (top) and after 2 additional Accent treatments spaced 2 weeks apart (bottom). The skin has tightened but the overall shape of the arm is unchanged in both photographs. However, the patient commented that after her 2 Accent treatments on her right arm, her clothes no longer felt tight. Photographs were compared by using Mirror DPS version 7.0 (Canfield Clinical Systems, Fairfield, NJ). They were made the same size by using angiomas as landmarks and making them the same distance apart on the before and after images.



The patient in the present study was treated in the left upper arm first with the unipolar handpiece for the first 6 treatments, and with the combination of unipolar and bipolar handpieces for the last 3 treatments. The post-treatment increase in tightening, firmness, and texture of the skin is consistent with the hypothesis of Emilia del Pino and colleagues, which states that unipolar RF energy stimulates contraction of collagen fibers by heating subcutaneous adipose tissue.<sup>4</sup> Additional skin tightening in the patient of the present study probably occurred as a result of local bipolar RF-induced dermal heating and subsequent contraction of collagen.

This study raises several questions: (1) How do the Accent and ThermaCool devices affect fat volume in nonfacial areas? (2) What effect will additional treatments by either or both devices have on volume reduction? (3) What mechanisms are responsible for the differences in volume reduction by both devices?

### Conclusion

On the upper arm, the Accent RF device provides improvements in skin laxity, texture, and firmness at least comparable to that of the ThermaCool and without adverse effects. The Accent treatments also provide volume reduction in the left arm by a mechanism not yet determined. Studies of the efficacy and safety of the Accent device with more patients and on other body areas are warranted.

### Disclosure

Dr. Mayoral received no funding for this study. She receives research support from and is a funded speaker for Thermage, Inc.

### References

- Doshi SN, Alster TS. Combination radiofrequency and diode laser for treatment of facial rhytides and skin laxity. *J Cosmet Laser Ther.* 2005;7:11-15.
- Sadick N, Alexiades-Armenakis M, Bitter P Jr., Hruza G, Mulholland RS. Enhanced full-face skin rejuvenation using synchronous intense pulsed optical and conducted bipolar radiofrequency energy (ELOS): introducing selective radiophotothermolysis. *J Drugs Dermatol.* 2005;4:181-186.
- Alexiades-Armenakis M. Rhytides, laxity, and photoaging treated with a combination of radiofrequency, diode laser, and pulsed light and assessed with a comprehensive grading scale. *J Drugs Dermatol.* 2006;5:731-738.
- Emilia del Pino M, Rosado RH, Azuela A, et al. Effect of controlled volumetric tissue heating with radiofrequency on cellulite and the subcutaneous tissue of the buttocks and thighs. *J Drugs Dermatol.* 2006;5:714-722.
- Zelickson B, Kist D, Bernstein E, et al. Histological and ultrastructural evaluation of the effects of a radiofrequency-based nonablative dermal remodeling device: a pilot study. *Arch Dermatol.* 2004;140:204-209.
- Hsu T, Kaminer M. The use of nonablative radiofrequency technology to tighten the lower face and neck. *Semin Cutan Med Surg.* 2003;22:115-123.
- Kist D, Burns AJ, Sanner R, Counters J, Zelickson B. Ultrastructural evaluation of multiple pass low energy versus single pass high energy radio-frequency treatment. *Lasers Surg Med.* 2006;38:150-154.
- Burns AJ, Holden SG. Monopolar radiofrequency tissue tightening—how we do it in our practice. *Lasers Surg Med.* 2006;38:575-579.
- Narins D, Narins R. Non-surgical radiofrequency facelift. *J Drugs Dermatol.* 2003;2:495-500.
- Narins RS, Tope WD, Pope K, Ross E. Overtreatment effects associated with a radiofrequency tissue-tightening device: rare, preventable, and correctable with subcision and autologous fat transfer. *Dermatol Surg.* 2006;32:115-124.
- Iyer S, Suthamjariya K, Fitzpatrick R. Using a radiofrequency energy device to treat the lower face: a treatment paradigm for a non-surgical facelift. *Cosmetic Dermatol.* 2003;16:37-40.
- Weiss RA, Weiss MA, Munavalli G, Beasley KL. Monopolar radiofrequency facial tightening: a retrospective analysis of efficacy and safety in over 600 treatments. *J Drugs Dermatol.* 2006;5:707-712.
- Finzi E, Spangler A. Multipass vector (mpave) technique with nonablative radiofrequency to treat facial and neck laxity. *Dermatol Surg.* 2005;31(pt 1):916-922.
- Hardaway CA, Ross EV. Nonablative laser skin remodeling. *Dermatol Clin.* 2002;20:97-111, ix.
- Ruiz-Esparza J, Gomez J. The medical face lift: a noninvasive, non-surgical approach to tissue tightening in facial skin using nonablative radiofrequency. *Dermatol Surg.* 2003;29:325-332.
- Fritz M, Counters JT, Zelickson BD. Radiofrequency treatment for middle and lower face laxity. *Arch Facial Plast Surg.* 2004;6:370-373.

### ADDRESS FOR CORRESPONDENCE

Flor Mayoral MD  
7300 SW 62nd Place  
PH West  
South Miami, FL 33143  
phone: 305-665-6166  
fax: 305-662-4649  
e-mail: flormayoral@aol.com